

# Clinical Significance of Sentinel Lymph Node Detection in Patients with Invasive Cervical Cancer

I. G. Sinilkin<sup>1</sup>, V. I. Chernov<sup>1,2</sup>, A. Yu. Lyapunov<sup>1,a)</sup>, A. A. Medvedeva<sup>1</sup>,  
R. V. Zelchan<sup>1</sup>, A. L. Chernyshova<sup>1</sup>, L. A. Kolomiets<sup>1</sup>, and O. D. Bragina<sup>1</sup>

<sup>1</sup> *Cancer Research Institute, Tomsk National Research Medical Center of the Russian Academy of Sciences, Tomsk, 634050 Russia*

<sup>2</sup> *National Research Tomsk Polytechnic University, Tomsk, 634050 Russia*

<sup>a)</sup> Corresponding author: Lyapunov1720.90@mail.ru

**Abstract.** The clinical significance of determining sentinel lymph nodes (SLN) in patients with invasive cervical cancer was studied. From 2013 to 2014, 30 cervical cancer patients (T1a1NxM0–T1b1NxM0) were treated at the Gynecological Oncology Department of the Cancer Research Institute. The day before surgery, four submucosal injections of 99mTc-Al2O3 at a total dose of 80 MBq were made in each quadrant around the cervical tumor. Patients were submitted to preoperative lymphoscintigraphy and intraoperative SLN detection. The feasibility of preserving the reproductive potential in patients after radical abdominal trachelectomy was assessed. The 3-year, overall, disease-free and metastasis-free survival rates were analyzed. Thirty-four SLNs were detected by single-photon emission computed tomography (SPECT) and 42 SLNs were identified by intraoperative gamma probe. The sensitivity in detecting SLNs was 100% for intraoperative SLN identification and 80% for SPECT image. The reproductive potential was preserved in 86% of patients. The 3-year overall and metastases-free survival rates were 100%. Recurrence occurred in 8.6% of cases.

Cervical cancer is the 5th most common cancer in women worldwide, reaching peak incidence in the 15 to 39 age group [1, 2]. The treatment of early-stage cervical cancer can be life-saving for majority of patients, however, there is a high risk of irreversible infertility development [3, 4]. High survival rates in women of the reproductive age with early-stage cervical cancer encourage oncologists to improve the patients' quality of life by performing an organ-preserving and functionally-sparing treatment [5–7]. Over the past years, abdominal radical trachelectomy has become more widely used for treating young women with FIGO stage IA2-IB2 invasive cervical cancer [1, 8, 9]. Radical abdominal trachelectomy (RAT) is a surgical procedure that removes the cervix, upper one-third of the vagina and lymph nodes in the pelvis, while preserving the ovaries, fallopian tubes and the uterine corpus that enables subsequent pregnancy and childbirth [2, 10–13]. Pelvic lymphadenectomy is performed first and the removed lymph nodes are sent for routine pathological examination. If lymph nodes are positive, radical hysterectomy with ovarian transposition is performed. If cancer cells are not found in lymph nodes, the cervix with paracervical, parametrial tissues and upper one-third of the vagina are removed. A negative proximal resection margin should be histologically confirmed [1, 14, 15].

Thus, visualization and assessment of lymph nodes during surgical removal of the tumor in order to detect lymph node metastasis is of great importance. Micrometastases can only be diagnosed by microscopically, using morphological or molecular biology techniques [16–18].

Sentinel lymph node biopsy is becoming increasingly recognized as a standard technique for determining the status of lymphatic spread. The term “sentinel lymph node” was used for the first time by Gould in 1960 and supplemented then by R.M. Cabanas in 1977 [16, 19, 20]. The concept of sentinel lymph node is based on the theory of an orderly progression of tumor cells within the lymphatic system in the initial phase of the metastatic process, assuming that early lymphatic metastases are found first within the first-line tumor draining lymph node, the sentinel lymph node. If the SLN is free of metastatic disease, all other lymph nodes will also be free of disease [19, 21–23].

Clinically, radioactive nanocolloids have been used for investigations of lymphatic drainage, and recently, more specifically for identification of the sentinel node in investigations of metastatic spread of some cancers [1, 2, 24]. A specific feature of  $^{99m}\text{Tc}\text{-Al}_2\text{O}_3$ , a new radiopharmaceutical, is an organic coating of nanoparticles. During passage through the lymphatic system, nanoparticles lose their organic coating and accumulate in SLN without redistribution in the body. In addition,  $^{99m}\text{Tc}\text{-Al}_2\text{O}_3$  has an optimum nanoparticle size from 50 to 100 nm, whereby the tracer quickly leaves the injection site and migrates through the lymphatic system [6, 25, 26].

The purpose of the study was to evaluate the clinical significance of SLN detection in patients with invasive cervical cancer using  $^{99m}\text{Tc}\text{-Al}_2\text{O}_3$ , a new radiotracer based on technetium-99m-labeled gamma-alumina, to assess the reproductive potential of these patients and to analyze 3-year overall, disease-free and metastases-free survival rates [3, 4].

## MATERIALS AND METHODS

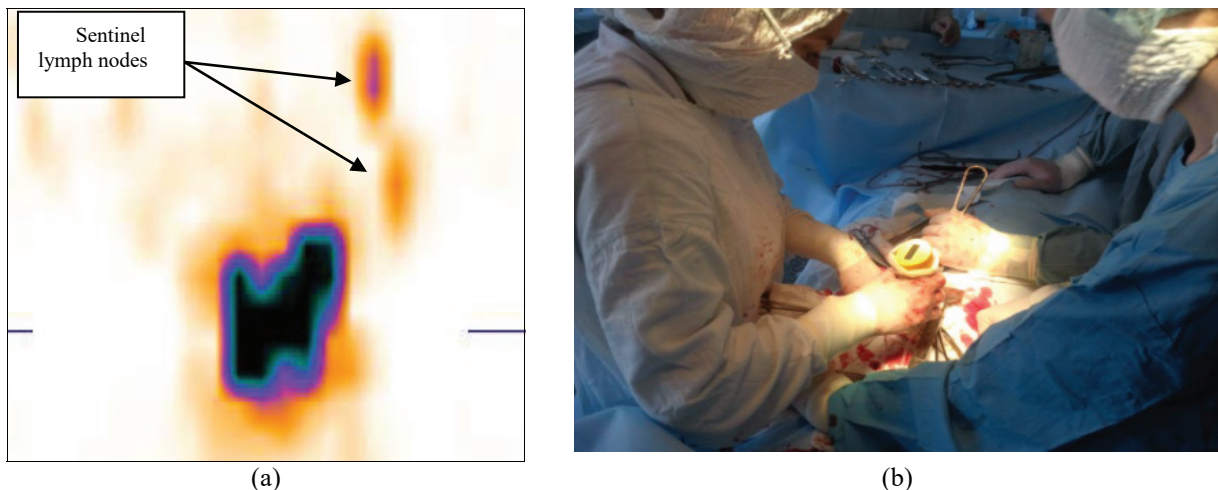
Between 2013 and 2014, 30 patients with histologically verified cervical cancer (T1a1NxM0–T1b1NxM0) were treated at the Gynecological Oncology Department of the Cancer Research Institute.

The day before surgery, four submucosal injections of  $^{99m}\text{Tc}\text{-Al}_2\text{O}_3$  at a total dose of 80 MBq (20 MBq per quadrant) were made around the cervical tumor. All patients were submitted to single photon emission computed tomography (SPECT) of the pelvis 18 hours after the injection of the radioactive isotope. Images were obtained using a double-headed gamma-camera (E.CAM 180, Siemens). A total of 16 projection images were recorded into a  $64 \times 64$  matrix (30 s per projection). The scan images were analyzed using the manufacturer software (e.soft, Siemens, Germany). Three-dimensional images of the abdomen, sagittal, transverse and coronal sections were obtained.

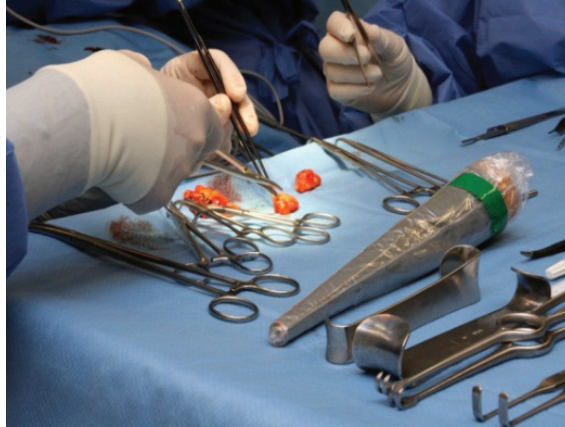
For intraoperative detection of sentinel lymph nodes, the hand-held collimated Gamma Finder II® probe was used, which allowed the surgeon to precisely locate gamma radiation source and obtain accurate information about the distribution of the radionuclide in tissues and organs of the patient. The intraoperative detection of SLNs was performed by the surgeon after the opening of the retroperitoneal space. The registered gamma radiation level was displayed in numerical values (Fig. 1).

Then the patients underwent iliac-pelvic lymph node dissection. After lymph node dissection, the removed lymph nodes were re-examined with gamma probe to detect SLNs missed during intraoperative examination. The sentinel lymph node was marked and separately sent for express cytological examination (Fig. 2).

Patients, who had no metastases in SLNs, underwent radical abdominal trachelectomy. In cases with metastatic SLNs, extended hysterectomy with ovarian transposition was performed. Statistical analysis was performed using the IBM SPSS statistics 20.0 package.



**FIGURE 1.** (a) Single photon emission computed tomography of the pelvis after injection of  $^{99m}\text{Tc}\text{-Al}_2\text{O}_3$ ; (b) intraoperative SLN identification using Gamma Finder II®



**FIGURE 2.** Re-examination of the removed lymph nodes using GammaFinder II®

The feasibility of preserving the reproductive potential was assessed in the group of patients who underwent organ-preserving treatment. To evaluate the reproductive potential preservation, the hormonal status of the ovaries was assessed by analyzing the levels of LH, FSH, estradiol, progesterone and testosterone. The maintenance of menstrual function after the treatment was also evaluated. The evaluation of the reproductive potential was carried out according to the formula: preservation of the reproductive potential (%) = all patients with the preserved hormonal and menstrual function/all patients in whom radical abdominal trachelectomy had been attempted X 100%.

The 3-year overall, disease-free and metastases-free survival rates were assessed in all patients.

## **RESULTS AND DISCUSSION**

The use of  $^{99m}\text{Tc-AI}_2\text{O}_3$  enabled SLNs to be identified by SPECT and intraoperative gamma probe procedure in all patients. A total of 34 SLNs were identified by SPECT. The intraoperative SLN assessment followed by the measurement of radioactivity in the removed lymph nodes allowed identification of 42 SLNs. The percentage of radiotracer uptake in SLNs was 7% by SPECT and 24% during surgery. The most common site for SLN detection was the external iliac region (57.2%), followed by the internal iliac (21.4%) and obturator (21.4%) regions. The comparison between the two techniques of SLN detection revealed that the intraoperative gamma probe detection technique was more effective than SPECT, demonstrating sensitivity of 100% compared to 80%. Imprint cytology and routine histological examination revealed metastases in regional lymph nodes in 6 patients and positive resection margins in 1 patient. Thus, 23 patients underwent radical abdominal trachelectomy (organ-preserving surgery) and 7 patients underwent extended hysterectomy with ovarian transposition. All patients with regional lymph node metastases and positive resection margins received 2 cycles of adjuvant chemotherapy.

To analyze the reproductive potential, the level of sex hormones and preservation of menstrual function were taken into account. Menstrual function was restored in all patients within three months after surgery. The normal level of sex hormones was observed in 20 (86.7%) patients. The reproductive potential was preserved in 86.7% of patients who underwent organ-preserving treatment. Pregnancy occurred in 3 patients.

None of the patients died within 3 years after treatment. In the first year of follow-up, 2 patients developed anastomotic recurrence. These patients received chemotherapy and had no evidence of recurrence during the next two years. There were no distant metastases.

The problems of the therapeutic role of SLN biopsy and clinical significance of metastases, which could not be identified by traditional imaging methods, are of great importance. The SLN biopsy allows small samples of lymph node tissue with a high prognostic value to be obtained.

The concept of SLN is especially valuable in cases where the status of lymph nodes is the most important factor for performing organ-preserving or adjuvant treatment, however the therapeutic role of complete lymphadenectomy is not clear.

## CONCLUSION

The novel radiotracer based on  $^{99m}\text{Tc-Al}_2\text{O}_3$  has high accumulation in sentinel lymph nodes without the evidence of further redistribution along the lymphatic collector, thus significantly facilitating scintigraphic and intraoperative SLN identification. The use of  $^{99m}\text{Tc-Al}_2\text{O}_3$  for detecting SLNs in patients with invasive cervical cancer demonstrated 100% sensitivity.

1. Based on the results of SLN biopsy, an individualized approach to surgical treatment of patients with invasive cervical cancer was used. Organ-preserving surgery was performed in 76% of patients and extended hysterectomy with ovarian transposition was performed in 24% of patients. The reproductive potential was preserved in 86.7% of patients.

2. The 3-year overall and metastases-free survival rates were 100%. Anastomotic recurrence was observed in 2 patients (8.6%).

## REFERENCES

1. I. Sinilkin, V. Chernov, A. Chernyshova, L. Kolomiets, A. Titskaya, R. Zelchan, O. Bragina, A. Lyapunov, and V. Skuridin, *EANM Congress* (Hamburg, Germany, 2015).
2. V. Chernov, I. Sinilkin, R. Zelchan, A. Medvedeva, A. Lyapunov, O. Bragina, N. Varlamova, and V. Skuridin, *AIP Conf. Proc.* **1760**, 020012 (2016). doi 10.1063/1.4960231
3. I. R. Jimenez, M. Roca, E. Vega, M. L. García, A. Benitez, M. Bajén, et al., *Nucl. Med. Commun.* **29**, 166–172 (2008).
4. C. Tax, M. M. Rovers, C. de Graaf, P. L. Zusterzeel, and R. L. Bekkers, *Gynecol. Oncol.* **139**(3), 559–567 (2015).
5. A. Rogov, V. Skuridin, E. Stasyuk, E. Nesterov, E. Ilina, V. Sadkin, V. Chernov, R. Zelchan, and L. Larionova, *Eur. J. Nucl. Med. Mol. Imaging* **42**(Suppl 1), 856 (2015).
6. V. Chernov, I. Sinilkin, E. Choyzonov, S. Chijevskaya, A. Titskaya, R. Zelchan, O. Bragina, A. Lyapunov, and V. Skuridin, *EANM Congress* (Hamburg, Germany, 2015).
7. S. Ogawa, H. Kobayashi, and S. Amada, *Int. J. Clin. Oncol.* **15**(1), 52–58 (2010).
8. J. P. Diaz, Y. Sonodab and M. M. Leitao, *Gynecol. Oncol.* **111**(2), 255–260 (2008).
9. H. Niikura, C. Okamura, J. Akahira, et al., *Gynecol. Oncol.* **94**, 528–532 (2004).
10. X.-l. Du, X.-G. Sheng, and T. Jiang, *China BMC Cancer* **11**, 157 (2011).
11. A. N. Fader, R. P. Edwards, and M. Cost, *Gynecol. Oncol.* **111**(1), 13–17 (2008).
12. A. J. Schauer, et al. (Springer, Berlin, 2005).
13. R. Wuntakal, A. J. Papadopoulos, S. A. Montalto, M. Perovic, M. Coutts, and O. Devaja, *Int. J. Gynecol. Cancer* **25**(9), 1663–1668 (2015).
14. R. Zeltchan, A. Medvedeva, I. Sinilkin, O. Bragina, V. Chernov, E. Stasyuk, A. Rogov, E. Il'ina, L. Larionova, V. Skuridin, and A. Dergilev, *IOP Conf. Mater. Sci. Eng.* **135**, 012054 (2016). doi 10.1088/1757-899X/135/1/012054
15. C. Levenback, *Gynecol. Oncol.* **111**(2 Suppl), S42–S43 (2008).
16. A. L. Chernyshova, L. A. Kolomiets., I. G. Sinilkin, V. I. Chernov, and A. Yu. Lyapunov, *AIP Conf. Proc. C*, 020013-1–020013-4 (2016).
17. S. J. Seong, H. Park, and K. M. Yang, *J. Korean Med. Sci.* **22**(1), 105–109 (2007).
18. P. P. Kara, A. Ayhan, B. Caner, et al., *Ann. Nucl. Med.* **22**(6), 487–494 (2008).
19. A. L. Chernyshova, L. A. Kolomiets., I. G. Sinilkin, V. I. Chernov, and A. Yu. Lyapunov, *Questions Oncol.* **62**(6), 807–811 (2016).
20. S. J. Seong, H. Park, K. M. Yang, et al., *J. Korean Med. Sci.* **22**(1), 105–109 (2007).
21. H. Niikura, C. Okamura, and J. Akahira, *Gynecol. Oncol.* **94**, 528–532 (2004).
22. T. Yamashita, H. Katayama, and Y. Kato, *Int. J. Gynecol. Cancer* **19**(6), 1113–1118 (2009).
23. P. Paredes, *J. Nucl. Med.* **32**(11), 1283–1287 (2005).
24. H. Hertel, C. Köhler, and D. Grund, *Gynecol. Oncol.* **103**(2), 506–511 (2006).
25. L. Darlin, J. Persson, and T. Bossmar, *Gynecol. Oncol.* **117**(2), 266–269 (2010).
26. P. Veronesi, O. Gentilini, J. R. Fernandez, and F. Magnoni, *Breast.* **18**(Suppl 3), 90–92 (2009).