

Nuclear Medicine Imaging of Locally Advanced Laryngeal and Hypopharyngeal Cancer

A. Medvedeva^{1,2,a)}, V. Chernov^{1,2}, R. Zeltchan^{1,2}, I. Sinilkin^{1,2}, O. Bragina^{1,2},
S. Chijevskaya¹, E. Choyzonov¹, and A. Goldberg¹

¹ *Cancer Research Institute, Tomsk National Research Medical Center of the Russian Academy of Sciences,
Tomsk, 634050 Russia*

² *National Research Tomsk Polytechnic University, Tomsk, 634050 Russia*

^{a)} Corresponding author: medvedeva@tnimc.ru

Abstract. The diagnostic capabilities of nuclear medicine imaging in the detection and assessment of the spread of laryngeal/hypopharyngeal cancer were studied. A total of 40 patients with histologically verified laryngeal and hypopharyngeal cancer and 20 patients with benign laryngeal lesions were included into the study. Submucosal injections of ^{99m}Tc-MIBI and ^{99m}Tc-Alotech were made around the tumor. Single photon emission computed tomography (SPECT) was performed 20 minutes after the injection of ^{99m}Tc-MIBI. Sentinel lymph nodes (SLNs) were detected in 26 patients. In 18 hours after the injection of ^{99m}Tc-Alotech, SPECT was performed. In 24 hours after the injection of ^{99m}Tc-Alotech, intraoperative SLN detection was performed using Gamma Finder II. SPECT with ^{99m}Tc-MIBI revealed laryngeal and hypopharyngeal tumors in 38 of the 40 patients. The ^{99m}Tc-MIBI uptake in metastatic lymph nodes was visualized in 2 (17%) of the 12 patients. Twenty eight SLNs were detected by SPECT and 31 SLNs were identified using the intraoperative gamma probe. The percentage of ^{99m}Tc-Alotech in the SLN was 5–10% of the radioactivity in the injection site by SPECT and 18–33% by intraoperative gamma probe detection. Thus, SPECT with ^{99m}Tc-MIBI is an effective tool for the diagnosis of laryngeal/hypopharyngeal cancer. The sensitivity, specificity and accuracy of this technique were 95%, 80% and 92%, respectively. The use of ^{99m}Tc-Alotech for the detection of SLNs in patients with laryngeal/hypopharyngeal cancer is characterized by 92.8% sensitivity.

INTRODUCTION

In Russia, the incidence rate for laryngeal and hypopharyngeal cancer is 2.9 per 100,000. Laryngeal/hypopharyngeal cancer occurs more frequently in males than in females (6.69/100.000 males). Laryngeal/hypopharyngeal cancer comprises 60–70% of all upper respiratory tract cancer cases [1, 2]. Despite advances in diagnostic imaging techniques, 60–70% of patients diagnosed with laryngeal/hypopharyngeal cancer have stage II or IV cancer. Cancer in situ is detected only in 2.3–6% of cases, stage I cancer is diagnosed in 23.9% of initially diagnosed tumors [3, 4].

The choice of adequate treatment and survival rates in cancer patients significantly depend on the precise detection of the primary tumor and the assessment of the extent of cancer involvement. Despite advances in the treatment of laryngeal/hypopharyngeal cancer, many aspects of this problem are still unresolved. For example, due to the introduction of new methods of conservative treatment into clinical practice and the popularization of organ-preserving surgeries, the early diagnosis of recurrent cancer is of great importance [5, 6].

Nowadays, surgery remains the common surgical procedure for patients with laryngeal/hypopharyngeal cancer. One of the main factors determining the tactics of surgical treatment and disease prognosis is the assessment of regional lymph node involvement. Lymph node metastatic tumors occur in 30% of patients having no clinical evidence of regional lymph node metastasis [7, 8]. Neck lymphadenectomy is the gold standard for the diagnosis in patients without clinical evidence of lymph node involvement. However, radical lymph node dissection adversely affects the postoperative period, increasing the healing time and the number of complications. Recently, there has

been increasing evidence that selective lymphadenectomy is as effective as radical lymphadenectomy for patients having no clinical evidence of lymph node metastases. Thus, the use of the SLN concept for laryngeal/hypopharyngeal cancer tends to reduce unjustified lymph node dissection. In recent years, nuclear medicine imaging techniques have proven to be promising for the SLN detection in melanoma and breast cancer [9–12]. The sentinel lymph node is defined as the first lymph node of an anatomical region reached by the lymphatic drainage. If the SLN is free of metastatic disease, all other lymph nodes will also be free of disease [13].

Nowadays, indirect and direct laryngoscopy, fibrolaryngoscopy, computed tomography, ultrasound examination of regional lymph nodes and magnetic resonance imaging are the standard diagnostic imaging modalities for the detection of laryngeal/hypopharyngeal cancer [14, 15]. Nuclear medicine imaging is often used as an additional source of information, the distinguishing feature of which is functionality: without having such a high spatial resolution as images obtained by X-ray or magnetic resonance imaging, the radiopharmaceuticals are capable of reflecting physiological and pathophysiological changes occurring in the tumor and surrounding tissues [16–18]. Positron emission tomography (PET) is currently used in large research centers for these purposes, and fluorodeoxyglucose labeled with ^{18}F (^{18}F -FDG) is commonly used in cancer detection. However, the use of this method in the detection of head and neck tumors is limited to a number of physiological features of this area. Normally, the increased physiological accumulation of ^{18}F -FDG is observed in the lymphoid tissue of the Waldeyer's ring, in the submandibular glands, in the striated muscles of the orbit, facial skull, tongue, neck and larynx.

Gamma-emitting radiopharmaceuticals with various mechanisms of accumulation in tumor tissue are also widely used in Russia. One of the most common radiotracers is $^{99\text{m}}\text{Tc}$ -methoxy-isobutyl-isonitrile (MIBI), which is characterized by nonspecific accumulation in tumor tissue. The use of $^{99\text{m}}\text{Tc}$ -MIBI for cancer detection is widely discussed in the specialized literature. Most of these studies concern tumors of the breast, lungs, and musculoskeletal system [19–22].

Single-photon emission computed tomography (SPECT) with $^{99\text{m}}\text{Tc}$ -MIBI is reported to be comparable with CT or MRI sensitivity and characterized by a rather high specificity in the detection of laryngeal/hypopharyngeal cancer [23]. There are reports on the use of SPECT with $^{99\text{m}}\text{Tc}$ -MIBI for both primary diagnosis and evaluation of the treatment outcomes of head and neck tumors [23, 24].

It should be noted that the methodological approaches to the detection of SLNs in tumors of various localizations are currently widely discussed. In particular, the methods for SLN identification using $^{99\text{m}}\text{Tc}$ -labeled nanocolloid [25] and lymphotropic dyes (lymphazurin, methylene blue) are widely used now. Most authors recommend using both methods for one patient [26]. New technologies for visualizing sentinel lymph nodes are being actively developed, in particular those based on infrared fluorescence. The quality of visualization and toxicity of the drug are currently studied in laboratory animals [27], this technique is not yet available for clinical practice.

For the detection of SLNs, there are several radiopharmaceuticals based on colloids [10, 13]. In Russia to date there are no radiopharmaceuticals registered for the visualization of SLNs. The original radiopharmaceutical based on technetium-99m-labeled gamma-alumina ($^{99\text{m}}\text{Tc}$ -Al $_{2}\text{O}_3$) was developed at Tomsk Cancer Research Institute and Tomsk Polytechnic University. Currently, this radiopharmaceutical has the trade name “ $^{99\text{m}}\text{Tc}$ -Alotech”. Preclinical studies showed its low toxicity and functional feasibility for SLN imaging [28, 29].

MATERIALS AND METHODS

The study included 40 patients with histologically verified laryngeal and hypopharyngeal cancer and 20 patients with benign laryngeal lesions. Twenty-eight patients underwent SPECT using the dual-head gamma camera (E.CAM 180, Siemens, Germany). For intraoperative SLN detection, the hand-held collimated Gamma Finder II® probe was used. $^{99\text{m}}\text{Tc}$ -MIBI and $^{99\text{m}}\text{Tc}$ -Alotech were used as radiopharmaceuticals. All patients were intravenously injected with $^{99\text{m}}\text{Tc}$ -MIBI at a dose of 740 MBq. Single photon emission computed tomography was performed 15–20 min after the tracer injection. The images were obtained with patients lying in the supine position and the detector's field of the view encompassed the head and neck region. A total of 32 projection images were recorded into a 64×64 matrix (30 s per projection). The scan images were analyzed using the manufacturer software (E.Soft, Siemens, Germany). Three-dimensional images of the chest, sagittal, transverse and coronal sections were obtained. The single photon emission computed tomography scans were visually assessed. The images of contralateral areas were compared and asymmetrically increased radiotracer uptake was considered pathological.

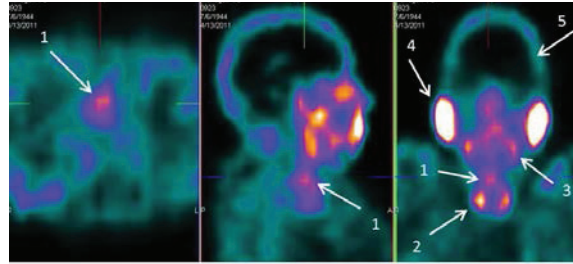


FIGURE 1. SPECT with ^{99m}Tc -MIBI in the patient with stage $\text{T}_2\text{N}_0\text{M}_0$ laryngeal cancer: increased accumulation of the radiopharmaceutical in the projection of right parts of the larynx (tumor of the right vocal fold) (1), increased accumulation of the radiopharmaceutical in the projection of the thyroid gland (2), increased accumulation of the radiopharmaceutical in the projection of submandibular salivary glands (3), increased accumulation of the radiopharmaceutical in the projection of parotid glands (4), increased accumulation of the radiopharmaceutical in the projection of aponeurotic helmet soft tissues (5)

Given the low anatomical and topographic resolutions of SPECT and due to the physical characteristics of obtaining scintigraphic images, it was not possible to accurately detect tumor localization in the larynx or hypopharynx. Therefore, we used findings of fibrolaryngoscopy and spiral computed tomography for more accurate tumor detection.

Four submucosal injections of ^{99m}Tc -Alotech at a dose of 20 MBq per injection were made around the tumor. Single photon emission computed tomography of the head and neck region was performed 18 hours after the radiotracer injection. Intraoperative gamma probe detection of sentinel lymph nodes was performed 24 hours after the injection of ^{99m}Tc -Alotech, allowing the surgeon to precisely locate gamma radiation source and obtain accurate information about the distribution of the radionuclide in tissues and organs of the patient. The registered gamma radiation level was displayed in numerical values. The lymph node with radioactivity of at least three times more than the background counts was defined as a sentinel lymph node. The sentinel lymph node was marked and separately sent for express cytological examination.

After lymph node dissection, the removed lymph nodes were re-examined with gamma probe to detect SLNs missed during intraoperative examination. The true number of SLNs was calculated as the sum of SLNs identified intraoperatively and in the surgical specimen. No false-positive SLNs (SLNs identified by scintigraphy or intraoperatively, but not found in surgical specimens) were found.

RESULTS

Single photon emission computed tomography revealed abnormal ^{99m}Tc -MIBI uptake in the laryngeal and hypopharyngeal region in 38 of the 40 patients. The intensity of ^{99m}Tc -MIBI uptake also varied, but it was always higher than the relatively low accumulation of the radiopharmaceutical in surrounding anatomical structures, such as muscles, cartilage, and ligamentous apparatus. The exceptions were only various groups of salivary and thyroid glands, in which the intensity of the radiopharmaceutical accumulation was also high (Fig. 1).

In two cases, the tumor could not be detected. In the first case, the tumor size was approximately 6 mm, while the resolving power of even the most modern gamma cameras in the visualization of large lesions allows detection of tumors with a minimum size of 10 mm. In the second case, the tumor was large (>4 cm, $\text{T}_4\text{N}_0\text{M}_0$) with a decay cavity, impaired blood supply of the tumor limited the entry of the radiopharmaceutical into tumor cells. Thus, the sensitivity of SPECT with ^{99m}Tc -MIBI in the detection of laryngeal/hypopharyngeal cancer was 95%.

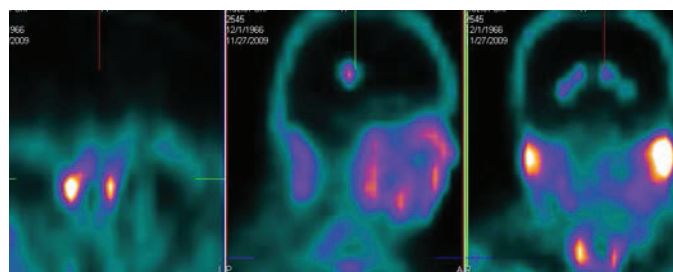


FIGURE 2. SPECT with ^{99m}Tc -MIBI. The patient with chronic hyperplastic laryngitis. There is no accumulation of the radiopharmaceutical in the projection of the larynx

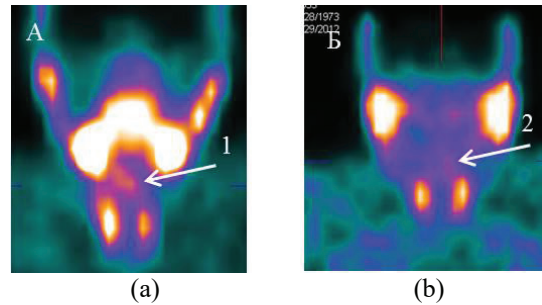


FIGURE 3. Results of SPECT with ^{99m}Tc -MIBI in 2 patients with chronic hyperplastic laryngitis, false-positive results: (a) increased accumulation of the radiopharmaceutical is visualized in the projection of the right larynx (1); (b) a site of low-intensity accumulation of the radiopharmaceutical with fuzzy contours in the projection of the left larynx is visualized (2)

To analyze the specificity of SPECT with ^{99m}Tc -MIBI, the study included patients with benign laryngeal diseases, who were examined using the same techniques as in the examination of patients with laryngeal and hypopharyngeal cancer. SPECT with ^{99m}Tc -MIBI revealed no abnormal accumulation of the radiopharmaceutical in the projection of the larynx in 8 of the 10 cases (Fig. 2) that was interpreted as a truly negative result and confirmed by morphological study.

A false positive result was observed in 2 patients with chronic hyperplastic laryngitis. The pathological process looked like a diffusely increased accumulation of the radiopharmaceutical with fuzzy contours. The intensity of accumulation of the radiopharmaceutical varied visually from medium to low values (Fig. 3).

To assess the regional tumor spread, submaxillary region and lateral parts of the neck were examined. The histological examination of the biopsy specimens revealed metastases in 12 (30%) patients. Single photon emission computed tomography with ^{99m}Tc -MIBI revealed abnormal accumulation of the radiopharmaceutical in the projection of metastatic lymph nodes in 2 (17%) of the 12 patients. Metastatic lymph nodes were visualized as increased accumulation of the radiopharmaceutical with uneven, fuzzy contours, non-uniform distribution of the radiopharmaceutical, usually of low intensity (Fig. 4).

The low sensitivity of SPECT with ^{99m}Tc -MIBI in the detection of metastases in regional lymph nodes was associated with the initially high accumulation of the radiopharmaceutical in the projection of the thyroid gland and submandibular salivary glands, screening the regions of the regional lymphatic collector.

New approaches to cancer treatment allowing surgeons to perform organ-preserving surgery have been widely introduced into clinical practice. Neoadjuvant radiation therapy or chemoradiotherapy for laryngeal cancer gives hope for organ preservation. Indeed, in 55–77% of cases such treatment allows complete regression and local control to be achieved. However, approximately a third of these patients have a local or regional relapse within the first year of follow-up [30]. As a rule, the development of laryngeal cancer recurrence after completion of radiotherapy or chemoradiotherapy is associated with morphofunctional changes in the larynx, thus making detection of recurrence difficult. Even CT and MRI have relatively low rates of specificity and sensitivity in the detection of laryngeal cancer recurrence (73–80% and 52–60%, respectively).

Our study included 10 patients with histologically verified laryngeal cancer. Single photon emission computed tomography with ^{99m}Tc -MIBI revealed asymmetric abnormal accumulation of the radiopharmaceutical in the recurrence area (Fig. 5). The sensitivity of SPECT with ^{99m}Tc -MIBI in the diagnosis of recurrence from laryngeal/hypopharyngeal cancer was 100%.

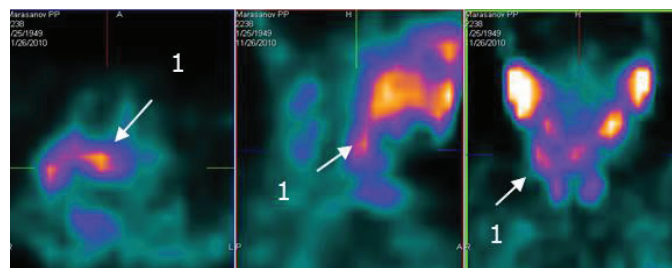


FIGURE 4. Results of SPECT with ^{99m}Tc -MIBI of the patient with stage $\text{T}_3\text{N}_1\text{M}_0$ laryngeal cancer: 1—increased accumulation of the radiopharmaceutical in the projection of the right submandibular metastatic lymph nodes

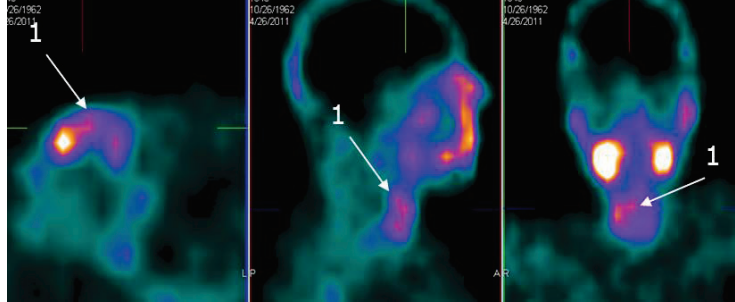


FIGURE 5. SPECT with ^{99m}Tc -MIBI image of the larynx: laryngeal cancer recurrence following chemoradiotherapy
Abnormal accumulation of the radiopharmaceutical is visualized in the right side of the larynx (1)

Single photon emission computed tomography of the head and neck region and intraoperative probe detection allowed SLN identification in all patients. Thus, the sensitivity of these techniques was 100%. Due to the fact that there were no cases with false-positive SLNs detected by SPECT or during surgery, the specificity of both techniques was also 100%. Single photon emission computed tomography revealed 28 SLNs in 26 patients, intraoperative radiometric measurement revealed 31 SLNs. The percentage of ^{99m}Tc -Alotech accumulation in the SLN was 5–10% (of the radioactivity in the injection site) by SPECT and 18–33% by intraoperative gamma probe detection. The most common site for SLN detection was the neck level III enclosing a carotid artery (54.5%), followed by the level IIA enclosing submandibular lymph nodes (27.2%), level IV (4.5%) and VI (13.6%) (Fig. 6).

Metastases in the excised SLNs were detected in 2 patients (11.8%). At 2-year follow-up, the patients with metastatic SLNs developed neck lymph node metastases. The patients underwent surgery followed by histological examination, which confirmed the presence of metastases in regional lymph nodes. Thus, the presence of metastases in the SLNs indicates tumor dissemination and the possible presence of clinically undetectable, occult metastases. In 15 patients (88.2%), all lymph nodes including SLNs and non-SLNs were metastasis-negative, thereby indicating that there was no phenomenon of “jumping” nodal metastases.

DISCUSSION

Single photon emission computed tomography with ^{99m}Tc -MIBI is an effective diagnostic tool for the detection of laryngeal/hypopharyngeal cancer. The sensitivity, specificity, and accuracy of the diagnosis were 95%, 80% and 92%, respectively. However, ^{99m}Tc -MIBI SPECT has a relatively low sensitivity for the detection of regional lymph nodes. The use of ^{99m}Tc -Alotech for the detection of SLNs in patients with laryngeal/hypopharyngeal cancer is characterized by a high sensitivity (92.8%). In our study, only radioactive nanocolloid was injected, however SLNs were intraoperatively detected in all patients. The high diagnostic efficiency of the technique is indirectly evidenced by the absence of so-called jumping metastases. Taking into account the follow-up results, we recommend performing surgery with lymph node dissection of the neck for the detection of metastases in SLNs.

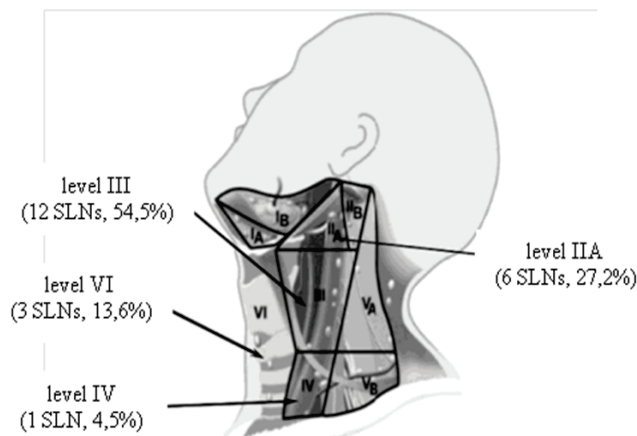


FIGURE 6. SLN detection in different levels of the neck

REFERENCES

1. V. I. Chissov, V. V. Starinskii, and G. V. Petrov, *Malignant Neoplasms in Russia in 2010: Morbidity and Mortality* (P. Herzen Moscow Oncology Research Institute, Moscow, 2012).
2. D. Kaprin, V. V. Starinskii, and G. V. Petrov, *Malignant Neoplasms in Russia in 2015 (Morbidity and Mortality)* (P. Herzen Moscow Oncology Research Institute, Moscow, 2017).
3. I. Paches, *Tumors of the Head and Neck* (Medicine, Moscow, 2000).
4. V. Reshetov and V. I. Chissov, *Cancer of the Laryngopharynx* (Medicine, Moscow, 2006).
5. O. N. Abdurahimov, "Comparative evaluation of the effectiveness of various methods of treatment of laryngeal cancer", Ph.D. thesis, Tashkent, 2002.
6. M. G. Majidov, *Russ. J. Oncol.* **2**, 41–42 (2005).
7. V. A. Rojnov, V. G. Andreev, Yu. S. Mardinskii, et al., *Sib. J. Oncol.* **29**(5), 23–26 (2008).
8. S. Chijevskaya, "Modern approaches to increasing the effectiveness of combined treatment and assessing the quality of life of patients with laryngeal and laryngeal cancer", Ph.D. thesis, Tomsk National Research Medical Center, 2013.
9. S. V. Kanaev, S. N. Novikov, L. A. Jukova, O. V. Zotova, V. F. Semiglazov, and P. V. Krivorot'ko, *Probl. Oncol.* **57**(5), 616–621 (2011).
10. S. G. Afanas'ev, A. V. Avgustinovich, V. I. Chernov, and I. G. Sinilkin, *Sib. J. Oncol.* **4**, 27–31 (2009).
11. R. Jimenez, M. Roca, E. Vega, M. L. García, A. Benitez, M. Bajén, et al., *Nucl. Med. Commun.* **29**, 166–172 (2008).
12. P. Paredes, *J. Nucl. Med.* **32**(11), 1283–1287 (2005).
13. J. Schauer, *The Sentinel Lymph Node Concept* (Springer, Berlin, 2005).
14. P. V. Vasil'ev, "Multispiral X-ray computed tomography in the diagnosis of larynx and laryngeal cancer," Ph.D. thesis, Pirogov Russian National Research Medical University, 2010.
15. P. V. Surkova, I. G. Frolova, E. Choyzonov, et al., *Sib. J. Oncol.* **44**(2), 39–44 (2011).
16. Yu. Lishmanov, V. Chernov, N. Krivonogov, G. Glukhov, and L. Maslova, *Med. Radiology Radiation Safety* **33**(3), 13–16 (1988).
17. V. Chernov, S. Triss, V. Skuridin, and Yu. Lishmanov, *Int. J. Cardiac. Imaging* **12**(2), 119–126 (1996).
18. R. Zelchan, V. Chernov, A. Medvedeva, I. Sinilkin, E. Stasyuk, A. Rogov, E. Il'ina, V. Skuridin and O. Bragina, *Eur. J. Nucl. Med. Mol. Imaging* **43**(1), 466 (2016).
19. A. Titskaya, V. Chernov, E. Slonimskaya, and I. Sinilkin, *Images Med. Radiology Radiation Safety* **53**(5), 51–60 (2008).
20. A. Medvedeva, V. Chernov, I. Sinilkin, R. Zelchan, Y. Belevich, S. Chizhevskaya, E. Slonimskaya, O. Bragina, and E. Choyzonov, *Eur. J. Nucl. Med. Mol. Imaging* **43**(1), 278 (2016).
21. Z. P. Li, Q. Liu, and S. Song, *Hell. J. Nucl. Med.* **20**(1), 26–35 (2017).
22. S. V. Kanaev, S. N. Novikov, D. S. Beñusov, E. V. Levchenko, M. M. Girshovich, A. I. Arse'ev, L. A. Zhukova, I. I. Semenov, P. I. Krzhivitskiĭ, V. F. Klimashevskiy, and R. Nazhmutdinov, *Probl. Oncol.* **60**(4), 476–481 (2014).
23. M. A. Rafique, R. A. Jafri, and S. Saeed, *Ann. NY Acad. Sci.* **1138**, 50–57 (2008).
24. M. Henze, A. Mohammed, and W. Mier, *Eur. J. Nucl. Med. Mol. Imaging* **29**, 324–330 (2002).
25. M. C. Kim, H. H. Kim, G. J. Jung, J. H. Lee, S. R. Choi, D. Y. Kang, M. S. Roh, and J. S. Jeong, *Ann. Surg.* **239**, 383–387 (2004).
26. H. Hayashi, T. Ochiai, M. Mori, T. Karube, T. Suzuki, Y. Gunji, S. Hori, N. Akutsu, H. Matsubara, and H. Shimada, *J. Am. Coll. Surg.* **196**, 68–74 (2003).
27. T. Koyama, A. Tsubota, K. Nariai, et al., *Lasers Surg. Med.* **39**, 76–82 (2007).
28. I. Sinilkin, V. Chernov, A. Chernyshova, L. Kolomiets, A. Titskaya, R. Zelchan, O. Bragina, A. Lyapunov, and V. Skuridin, *Eur. J. Nucl. Med. Mol. Imaging* **42**(1), 704 (2015).
29. V. Chernov, I. Sinilkin, E. Choyzonov, S. Chijevskaya, A. Titskaya, R. Zelchan, O. Bragina, A. Lyapunov, and V. Skuridin, *Eur. J. Nucl. Med. Mol. Imaging* **42**(1), 704 (2015).
30. S. Aladin, V. Korolev, and A. Vajenin, *Head Neck Tumors* **3**, 16–21 (2011).