

The Study of ^{99m}Tc -Aluminum Oxide Using for Sentinel Lymph Nodes Detection in Experiment

A.A. Medvedeva^{1,2}, I.G. Sinilkin^{1,2}, R.V. Zelchan^{1,2}, V.I. Chernov^{1,2},
A.Yu. Lyapunov¹, O.D. Bragina², N.V. Varlamova², V.S. Skuridin²,
A.P. Dergilev³

¹ Tomsk Cancer Research Institute, Kooperativny Street 5, Tomsk, Russia

² Tomsk Polytechnic University, Lenin Avenue 30, Tomsk, Russia

³ Novosibirsk State Medical University, Krasny Prospect 52, Novosibirsk, Russia

E-mail: Chernov@oncology.tomsk.ru

Abstract: The purpose of the study was a comparative research of the possibility of using the radiopharmaceuticals $^{99m}\text{Tc}\text{-Al}_2\text{O}_3$ and $^{99m}\text{Tc}\text{-Nanocis}$ for visualizing sentinel lymph nodes in the experiment. Measurement of the sizes of $^{99m}\text{Tc}\text{-Al}_2\text{O}_3$ and $^{99m}\text{Tc}\text{-Nanocis}$ colloidal particles was performed in seven series of radiopharmaceuticals. Pharmacokinetics of $^{99m}\text{Tc}\text{-Al}_2\text{O}_3$ and $^{99m}\text{Tc}\text{-Nanocis}$ was researched on 50 white male rats. The possibility of the use of $^{99m}\text{Tc}\text{-Al}_2\text{O}_3$ and $^{99m}\text{Tc}\text{-Nanocis}$ for lymphoscintigraphy was studied in the experiments on 12 white male rats. Average dynamic diameter of the sol particle was 52-77 nm for $^{99m}\text{Tc}\text{-Al}_2\text{O}_3$ and 16.7-24.5 nm for $^{99m}\text{Tc}\text{-Nanocis}$. Radiopharmaceuticals accumulated in the inguinal lymph node – at 1 hour after administration the average uptake of $^{99m}\text{Tc}\text{-Al}_2\text{O}_3$ was 8.6% in it and the accumulation of $^{99m}\text{Tc}\text{-Nanocis}$ was significantly lower - 1.8% ($p < 0.05$). In all study point average uptake of $^{99m}\text{Tc}\text{-Al}_2\text{O}_3$ in the lymph node was significantly higher $^{99m}\text{Tc}\text{-Nanocis}$ accumulation. The results dynamic scintigraphic studies in rats showed that $^{99m}\text{Tc}\text{-Al}_2\text{O}_3$ and $^{99m}\text{Tc}\text{-Nanocis}$ actively accumulated into the lymphatic system. By using $^{99m}\text{Tc}\text{-Al}_2\text{O}_3$ inguinal lymph node was determined in 5 minutes after injection and clearly visualize in all the animals in the 15th minute, when the accumulation became more than 1% of the administered dose. Further observation indicated that the $^{99m}\text{Tc}\text{-Al}_2\text{O}_3$ accumulation reaches a plateau in a lymph node (average 10.5%) for 2 hour study and then its accumulation remains practically at the same level, slightly increasing to 12% at 24 hours. In the case of $^{99m}\text{Tc}\text{-Nanocis}$ inguinal lymph node visualized in all animals for 15 minutes when it was accumulated on the average 1.03% of the administered dose. Plateau of $^{99m}\text{Tc}\text{-Nanocis}$ accumulation in the lymph node (average 2.05%) occurred at 2 hour of the study and remained almost on the same level (in average 2.3%) to 24 hours. Thus, the experimental study of a new domestic radiopharmaceutical showed that the $^{99m}\text{Tc}\text{-Al}_2\text{O}_3$ several times actively accumulates in the lymph nodes as compared to imported analogue and its practical application will facilitate intraoperative identification of sentinel lymph nodes.

1. Introduction

In recent years radionuclide techniques have proven themselves to identify the sentinel lymph nodes (SLN) - first lymph nodes on the path of lymph drainage from a malignant tumor. These nodes, filter-



ing afferent lymph, become a “trap” for cancer cells, and that is why SLN biopsy with followed by histological examination is an objective diagnostic criterion for the lymphatic metastasis detection. It is believed that if the SLN are not affected by metastatic disease, all other regional lymph nodes remain intact [1-3, 5-7].

The world practice has considerable experience in relation to radionuclide visualization of SLN at melanoma and breast cancer. At tumors in other locations (lungs, head, neck, gastrointestinal tract, uterus) the effectiveness of this method is studied in scientific research [1-3, 6].

Optimal radiopharmaceuticals to identify SLN is colloid labeled with technetium-99m [1,6]. In Russian Federation, to identify the SLN has been applied colloidal rhenium sulphide (^{99m}Tc -Nanocis, CIS bio International). The main disadvantage of this radiopharmaceutical is the low level of accumulation in the SLN (1.5-2% of the administered dose) and redistribution to lymph nodes 2 and 3 orders, which reduces the specificity of SLN visualization [1, 3, 6, 7].

Currently, in the Russian Federation there are no registered radiopharmaceuticals for SLN imaging. In this regard, the Tomsk Cancer Research Institute and Tomsk Polytechnic University developed by the original radiopharmaceutical based on labeled with technetium-99m aluminum oxide (^{99m}Tc - Al_2O_3) (the project № 16.N08.12.1011 «Preclinical studies of new lymphotropic radiopharmaceutical labeled by technetium-99m aluminum oxide” Federal Program “Development of the Russian Federation, the pharmaceutical and medical industry period up to 2020 and beyond”).

The aim of present investigation was a comparative study of the possibility of using the radiopharmaceuticals ^{99m}Tc - Al_2O_3 and ^{99m}Tc -Nanocis for visualizing sentinel lymph nodes in the experiment.

2. Material and Methods

Measurement of the sizes of ^{99m}Tc - Al_2O_3 and ^{99m}Tc -Nanocis colloidal particles was performed in seven series of radiopharmaceuticals on apparatus NICOMP 380 ZLS (company PSS NICOMP, USA).

Pharmacokinetics of ^{99m}Tc - Al_2O_3 and ^{99m}Tc -Nanocis was researched on white male rats “Wistar” weighing 200-250 g; radiopharmaceuticals was injected between the first and second fingers of the hind paw subcutaneously in a dose of 30 MBq. Before the injection of radiotracer animals were anesthetized with ethyl ether. The volume of the injected dose was 0.1 ml (volume activity is 300 MBq/ml). The animals were decapitated in groups of 10 individuals (5 rats for each radiopharmaceutical) in 1, 2, 3, 5 and 24 h after injection of radiopharmaceuticals.

The recovered organs and tissues were packed into vials for weighing and direct radioactivity measurement. Standard radiopharmaceutical and bioassays have the same volume (after weighing vials filled with distilled water up to the same level) and the geometric form. Radioassay of blood and internal organs (the contents of the radiopharmaceutical as a percentage of the entered radioactivity per 1 ml of blood or 1 g of tissue or organ) performed on the radiometer RIS A1 (Russian Federation). For radiometric studies differential discriminator was set up on the photon peak of 140 keV, with a window width of 20%. According to the results of radioassay also determined the level of the radiopharmaceutical level in inguinal lymph node and injection site.

The possibility of the use of ^{99m}Tc - Al_2O_3 and ^{99m}Tc -Nanocis for lymphoscintigraphy was studied in the experiments on 12 white male rats “Wistar” (6 rats for each radiopharmaceutical) weighing 300-350 g. Before a single subcutaneous injection of radiopharmaceuticals between the first and second fingers of the hind paw at a dose of 18-20 MBq and during scintigraphic studies animals were anesthetized using ethyl ether. All scintigraphic studies were performed on the gamma-camera E-CAM-180 (Siemens, USA) with a setting up of a differential discriminator on a photon peak of 140 keV, with a window width of 20%, using a parallel low-energy high-resolution collimator. During the study animals were put with their ventral surface to the detector of the gamma camera so that the whole body of the animal appeared in picture. Since the introduction, kinetics of the distribution of radiopharmaceuticals through the organs and tissues was fixed by step-frame recording within 15 min (1 frame per minute), in the matrix of 64 * 64 pixels. Static scintigraphy was performed in 1, 2, 3 and 24 hours in the front and rear projections in the matrix of 256 x 256 with a set of 500 pulses per position. Accord-

ing to the results of scintigraphic studies the percent of radiopharmaceuticals accumulation in the inguinal lymph node and the injection site from administered dose were determined.

Keeping and participation of the animals in the experiment were performed in accordance with the rules adopted by the "European Convention for the Protection of Vertebrate Animals used for Experimental and other Scientific Purposes" (Strasbourg, 1986).

The data received were processed by the method of variation statistics using "STATGRAF" numeric package. Between-group comparisons were done by using the Wilcoxon rank-sum test.

3. Results and Discussion

Measurement of the sizes of radioactive particles of $^{99m}\text{Tc-Al}_2\text{O}_3$ and $^{99m}\text{Tc-Nanocis}$ in 7 batches showed that the average dynamic diameter of the sol particle was 52-77 nm for $^{99m}\text{Tc-Al}_2\text{O}_3$ and 16.7-24.5 nm for $^{99m}\text{Tc-Nanocis}$, which, according to the literature, is quite acceptable for scintigraphic visualization of lymph nodes [1, 3, 6].

Radiometry of rats organs showed that $^{99m}\text{Tc-Al}_2\text{O}_3$ and $^{99m}\text{Tc-Nanocis}$ actively withdrew subcutaneous injection spot - after 1 hour in the spot was about 2/3 of the administered dose (Table 1). After 24 hours at the injection site remained about half of the dose. Leaving the injection site, the radiopharmaceuticals accumulated in the inguinal lymph node – in 1 hour after administration the average accumulation of $^{99m}\text{Tc-Al}_2\text{O}_3$ was 8.6% in it and the accumulation of $^{99m}\text{Tc-Nanocis}$ was significantly lower - 1.8% ($p < 0.05$). In the second hour of study average accumulation of $^{99m}\text{Tc-Al}_2\text{O}_3$ in inguinal lymph node has exceeded 10% and in a day gradually increased to 12.8%. Accumulation of $^{99m}\text{Tc-Nanocis}$ after 2 hours reached 3.6% and slightly fluctuated at this level up to 24 hours of observation (Table 1). In all study point average accumulation of $^{99m}\text{Tc-Al}_2\text{O}_3$ in the lymph node was significantly higher $^{99m}\text{Tc-Nanocis}$ accumulation.

Received through the thoracic duct into the blood radiopharmaceuticals, very actively uptake in liver and spleen. The hepatic level of accumulation of $^{99m}\text{Tc-Al}_2\text{O}_3$ rise from 3.8% in 1 h after injection to 21.1% in 24 hours of the study, for $^{99m}\text{Tc-Nanocis}$ these values were 6.6% and 18.3%, respectively. In the spleen, the magnitude accumulation of $^{99m}\text{Tc-Al}_2\text{O}_3$ ranges from 1.5% (in 1 hour) to 4.5% (in 24 hours), the level of accumulation of $^{99m}\text{Tc-Nanocis}$ grew from 1.3% (in 1 hour) to 3.6% (in 24 hours). It was noted a slight content of radiopharmaceuticals in the heart, lungs and blood, which recorded less than 1% of the injected dose.

The results dynamic scintigraphic studies in rats showed that $^{99m}\text{Tc-Al}_2\text{O}_3$ and $^{99m}\text{Tc-Nanocis}$ actively accumulated into the lymphatic system from the injection site (Table. 2). After 2 hours at the injection site was 57% of the administered dose of $^{99m}\text{Tc-Al}_2\text{O}_3$ and 50.5% of $^{99m}\text{Tc-Nanocis}$. After 24 hours the injection spot was kept less than half the dose of the radiopharmaceuticals.

Table 1. The content of ^{99m}Tc in the organs and tissues of rats at different times after subcutaneous injection of radiotracer $^{99m}\text{Tc-Al}_2\text{O}_3$ and $^{99m}\text{Tc-Nanocis}$ according to direct radiometry.

Time		1h	2h	3h	5h	24h
$^{99m}\text{Tc-Al}_2\text{O}_3$						
Injection site	(%)	68.3±5.3	57.0±8.7	53.6±5.0	51.1±5.2	46.7±6.7
Lymph node	%	8.6± 1.1*	10.5± 1.6*	11.2± 1.6*	11.8± 1.9*	12.8± 1.4*
Blood	%/ml	0.91±0.01	0.26± 0.08	0.28± 0.08	0.30± 0.07	0.31±0.08+
Liver	%	0.33± 0.15	0.38± 0.11	0.45± 0.14	0.43± 0.12	0.35± 0.11
	%/g	0.13± 0.06	0.15± 0.05	0.18± 0.06	0.18± 0.05	0.14± 0.07
Stomach	%	3.8±1.2	9.6±1.1	12.1±2.4	16.8±1.8	21.1±1.6
	%/g	0.32±0.1	0.8±0.09	1.0±0.14	1.4±0.15	1.8±0.14
Spleen	%	1.5± 0.4	2.6± 0.6	4.1± 0.9	4.3± 0.8	4.5± 0.9

	%/g	0.74±0.2	1.4±0.29	2.1±0.43	2.2±0.4	2.2±0.42
Heart	%	0.41±0.11	0.29±0.12	0.67±1.08	0.6±0.07	0.9±0.1
	%/g	0.34±0.1	0.24±0.09	0.56±0.11	0.61±0.06	0.76±0.07
Lung	%	0.34±0.12	0.26±0.09	0.15±0.06	0.13±0.02	0.1±0.08
	%/g	0.12±0.05	0.09±0.04	0.06± 0.03	0.05± 0.04	0.04±0.3
^{99m}Tc-Nanocis						
Injection site	(%)	66.3±3.15	59.0±4.1	55.5±5.7	53.2±4.9	51.2±4.3
Lymph node	%	1.8± 1.2	3.6± 2.4	3.6± 1.8	3.6± 1.7	3.2± 1.0
Blood	%/ml	0.2±0.1	0.24± 0.04	0.27± 0.03	0.27± 0.07	0.3±0.1
Liver	%	1.2± 0.2	1.5± 0.2	1.5± 0.4	1.5± 0.7	2.2± 0.4
	%/g	0.48± 0.1	0.60± 0.15	0.62± 0.22	0.63± 0.31	0.88± 0.38
Stomach	%	6.6±0.3	10.5±0.9	13.9±2.07	16.3±1.9	18.3±1.4
	%/g	0.55±0.2	0.87±0.21	1.15±0.24	1.35±0.31	1.52±0.29
Spleen	%	1.3± 0.2	2.1± 0.3	2.8± 0.5	3.3± 0.7	3.6± 0.6
	%/g	0.65±0.1	1.1±0.15	1.4±0.14	1.65±0.2	1.80±0.2
Heart	%	0.3±0.1	0.3±0.06	0.31±0.09	0.3±0.11	0.4±0.15
	%/g	0.25±0.09	0.24±0.08	0.25±0.08	0.24±0.06	0.23±0.07
Lung	%	0.6±0.1	0.6±0.12	0.61±0.15	0.59±0.14	0.54±0.2
	%/g	0.22±0.09	0.22±0.1	0.23± 0.08	0.21± 0.06	0.20±0.1

* - p <0.05% compared to ^{99m}Tc-Nanocis

Table 2. The content of ^{99m}Tc at the injection site and inguinal lymph node after subcutaneous injection of radiotracer ^{99m}Tc-Al₂O₃ and ^{99m}Tc-Nanocis according to dynamic scintigraphy.

Localization	Time after the injection	Average accumulation of ^{99m} Tc-Al ₂ O ₃ (%)	Average accumulation of ^{99m} Tc-Nanocis (%)
Injection site	5 minutes	76.8±3.7	82.7±5.0
	15 minutes	71.3±4.2	67.7±3.0
	1 h	68.2±5.3	55.7±4.8
	2 h	57.0±8.6	50.5±5.1
	3 h	53.5±4.9	47.7±4.6
	24 h	46.7±6.8	35.33±3.3
Inguinal lymph node	5 minutes	0.9±0.2	0.98±0.22
	15 minutes	1.19±0.13	1.03±0.22
	1 h	8.6±1.1	1.4±0.86
	2 h	10.5±1.6	2.05±1.67
	3 h	11.1±1.2	2.18±1.57
	24 h	12.0±1.4	2.31±1.45

* - p <0.05% compared to ^{99m}Tc-Nanocis

By using ^{99m}Tc-Al₂O₃ inguinal lymph node was determined in 5 minutes after injection and clearly visualize in all the animals in the 15th minute, when the accumulation became more than 1% of the administered dose. Further observation indicated that the ^{99m}Tc-Al₂O₃ accumulation reaches a plateau in a lymph node (average 10.5%) for 2 hour study (Fig. 1) and then its accumulation remains practically at the same level, slightly increasing to 12% in 24 hours. In the case of ^{99m}Tc-Nanocis inguinal lymph node visualized in all animals for 15 minutes when it was accumulated on the average 1.03% of the administered dose.

Plateau of ^{99m}Tc-Nanocis accumulation in the lymph node (average 2.05%) occurred in 2 hour of the study (Fig. 1) and remained almost on the same level (in average 2.3%) to 24 hours.

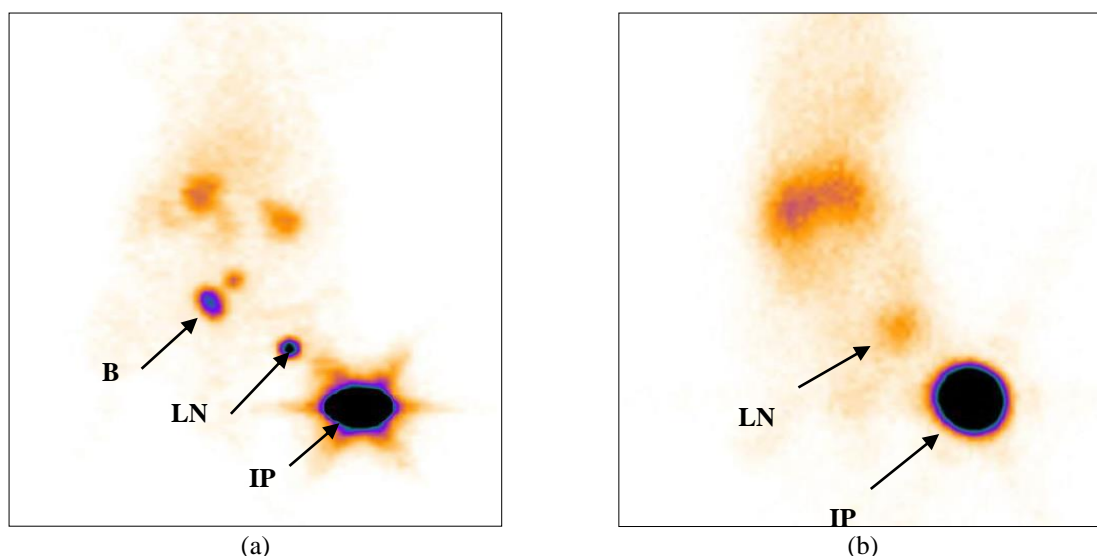


Figure 1. Scintigrams rats performed through 2 hours after injection of $^{99m}\text{Tc-Al}_2\text{O}_3$ (a) and $^{99m}\text{Tc-Nanocis}$ (b). A - The level of radioactivity in the injection point (IP) – 56.3% of the injected dose, in the inguinal lymph node (LN) – 11.2%. B - bladder. B - The level of radioactivity in the injection point (IP) – 61.3% of the injected dose, in the inguinal lymph node (LN) – 3.5%.

In oncology practice spot of radiopharmaceutical injections are often located in close proximity to the sentinel lymph node, making it difficult to visualize [1, 6].

We have established a multiple higher accumulation of $^{99m}\text{Tc-Al}_2\text{O}_3$ in SLM in comparison with import analogue. Considering this fact the clinical use of new domestic radiopharmaceutical will facilitate intraoperative identification of such nodes.

4. Conclusions

Thus, the experimental study of a new domestic radiopharmaceutical showed that the $^{99m}\text{Tc-Al}_2\text{O}_3$ several times actively accumulates in the lymph nodes as compared to imported analogue and its practical application will facilitate intraoperative identification of SLN.

References

- [1] Chernov VI, Sinilkin IG, Choyznzonov EC, Chijevskaya SY, Titskaya AA, Zelchan RV, Bragina OD, Lyapunov AY, Skuridin VS 2015 *Eur J Nucl Med Mol Imaging* **42** (Suppl 1) 704
- [2] Chernov VI, Sinilkin IG, Shiryaev SV. 2010 *National leadership on nuclear medicine* Ed. Lishmanov YB, Chernov VI Tomsk STT B **2** 336
- [3] Afanasyev SG, Avgustinovich AV, Chernov VI, Sinilkin IG 2009 *Siberian Journal of Oncology* **34** 27
- [4] Jimenez IR, Roca M, Vega E, García ML, Benitez A, Bajén M et al. 2008 *Nucl Med Commun* **29** 166
- [5] Paredes P, Vidal-Sicart S, Zanón G et al. 2005 *E.J.Nucl. Med.* **32** 1283
- [6] Schauer AJ et al. 2005 *The Sentinel Lymph Node Concept* Springer Berlin Heidelberg New York P 565
- [7] Sinilkin I, Chernov V, Zelchan R, Titskaya A, Skuridin V 2014 *Eur J Nucl Med Mol Imaging* **41** (Suppl 2) 518