

The use of $^{99m}\text{Tc-Al}_2\text{O}_3$ for detection of sentinel lymph nodes in cervical cancer patients

I G Sinilkin^{1,2}, V I Chernov^{1,2}, A Yu Lyapunov¹, A A Medvedeva^{1,2},
R V Zelchan^{1,2}, A L Chernyshova¹, L A Kolomiets^{1,3}

1Tomsk Cancer Research Institute, Russia, Tomsk, Kooperativny street, 5

2Tomsk Polytechnic University, Russia, Tomsk, Lenina street, 30

3Siberian State Medical University, Russia, Tomsk, Moskovsky Trakt, 2

E-mail: Lyapunov1720.90@mail.ru

Abstract: The purpose of the study was to evaluate the feasibility of using $^{99m}\text{Tc-Al}_2\text{O}_3$ -based radiopharmaceutical, a novel molecular imaging agent for sentinel lymph node detection in patients with invasive cervical cancer. The study included 23 cervical cancer patients (T1aNxMx- T2bNxMx) treated at the Tomsk Cancer Research Institute. At 18 hours before surgery, 80 MBq of the $^{99m}\text{Tc-Al}_2\text{O}_3$ were injected peritumorally, followed by single-photon emission computed tomography (SPECT) of the pelvis and intraoperative SLN identification. Twenty-seven SLNs were detected by SPECT, and 34 SLNs were identified by intraoperative gamma probe. The total number of identified SLNs per patient ranged from 1 to 3 (the mean number of SLNs was 1.4 per patient). The most common site for SLN detection was the external iliac region (57.2%), followed by the internal iliac, obturator, presacral and retrosacral regions (they amounted to 14%, respectively), and the parametrial region (1%). Sensitivity in detecting SLNs was 100% for intraoperative SLN identification and 79% for SPECT image.

1. Introduction

Cervical cancer is estimated to be the 2-nd most common cancer in women worldwide, accounting for 7% of malignancies in women. Approximately 15,000 new cases of invasive cervical cancer are diagnosed annually in Russia. The peak age at diagnosis of invasive cervical cancer is between 15 and 54 years [1].

The objective assessment of pelvic lymph nodes is an integral component of definitive surgical management for cervical cancer. Regional lymph node status reflects the metastatic potential of the tumor. Currently available non-invasive imaging methods such as ultrasound, computed tomography, magnetic resonance imaging and nuclear scintigraphy are unable to provide information about the presence or absence of lymph node metastases. Micrometastases can only be diagnosed by microscopically, using morphological or molecular biology techniques. Visualization and assessment of lymph nodes during surgical removal of the tumor in order to detect lymph node metastasis is of great importance [7].

Sentinel lymph node biopsy is becoming increasingly recognized as a standard technique for determining the status of lymphatic spread. The term “sentinel lymph node” was used for the first time by E.A. Gould in 1960 and supplemented then by R.M. Cabanas in 1977 [12, 13]. The concept of sentinel lymph node (SLN) is based on the theory of an orderly progression of tumor cells within the lymphatic system in the initial phase of the metastatic process, assuming that early lymphatic



metastases are found first within the first-line tumor draining lymph node, the sentinel lymph node [13]. If the SLN is free of metastatic disease, all other lymph nodes will also be free of disease. Identification of SLNs may help some patients avoid more extensive lymph node surgery, thus minimizing postoperative morbidity and significantly improving life quality of the patients.

Clinically, radioactive nanocolloids have been used for investigations of lymphatic drainage, and recently, more specifically for identification of the sentinel node in investigations of metastatic spread of some cancers [3, 9,14].

The use of radiopharmaceuticals for SLN detection such as Nanocoll, ^{99m}Tc -nanocolloid, Nanocis, Microlite and Sulfurcolloid have several drawbacks [10, 11]. Their applications are limited by their complex manufacturing process and high cost. Furthermore, the extremely low accumulation of these radiopharmaceuticals in SLNs may lead to further redistribution of a radiotracer through the lymphatic collector and an erroneous interpretation of the results [5, 9].

In this regard, there was a need to develop a novel lymphotropic radiopharmaceutical, which would be devoid of these drawbacks.

The basic precondition for using the nanoscale Al_2O_3 gamma-alumina as a "carrier" of ^{99m}Tc label is its lower toxicity compared with antimony and rhenium compounds in combination with good absorption properties, availability, and low cost.

A specific feature of this compound is an organic coating of nanoparticles [8]. During passage through the lymphatic system, nanoparticles lose their organic coating and persistent uptake in SLN without redistribution in the body. In addition, ^{99m}Tc - Al_2O_3 has an optimum nanoparticle size from 50 to 100 nm, whereby the tracer quickly leaves the injection site and migrates through the lymphatic system [3, 9, 14].

The purpose of the study was to evaluate the feasibility of using the new radiopharmaceutical, based on technetium-99m-labeled gamma-alumina (^{99m}Tc - Al_2O_3), for the detection of sentinel lymph nodes in cervical cancer patients.

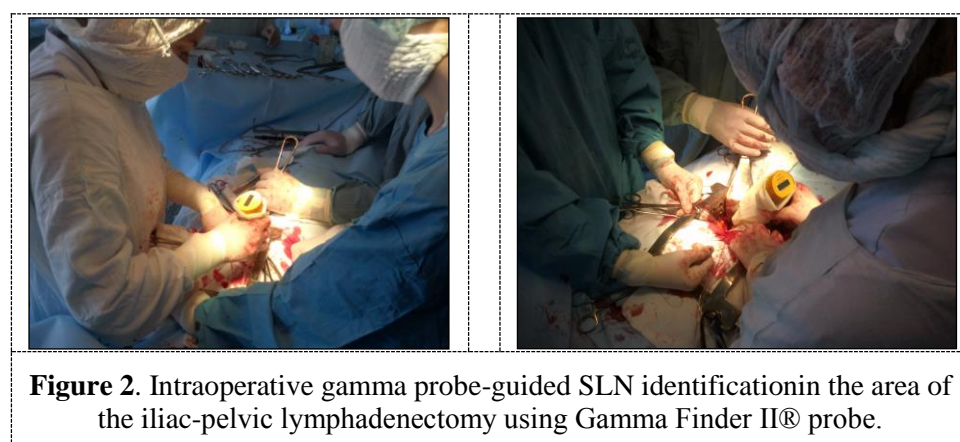
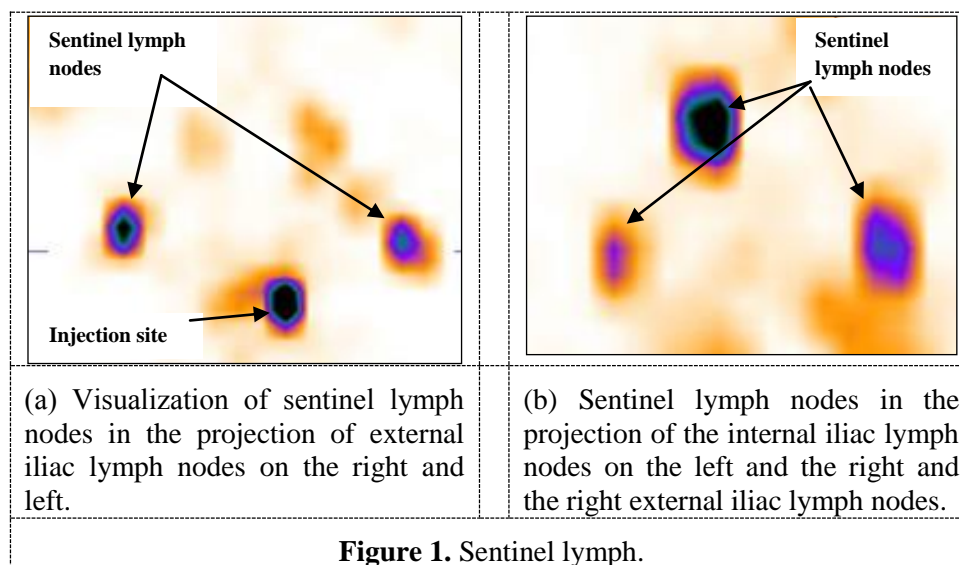
2. Materials and methods

Between 2015 and 2016, 23 patients with cervical cancer (T1aNxMx- T2bNxMx) were treated at the Gynecological Oncology Department of the Tomsk Cancer Research Institute. Non-keratinizing squamous cell carcinoma was histologically verified in all patients.

The day before surgery, four submucosal injections of ^{99m}Tc - Al_2O_3 at a dose of 20 MBq per quadrant were made in each quadrant around the cervical tumor. Patients were submitted to single photon emission computed tomography (SPECT) of the pelvis 18 hours after the injection of the radioactive isotope. Images were obtained using a double-headed gamma-camera (E.CAM 180, Siemens).

A total of 16 projection images were recorded into a 64x64 matrix (30 seconds per projection). The scan images were analyzed using the manufacturer software (e.soft, Siemens, Germany). Three-dimensional images of the abdomen, sagittal, transverse and coronal sections were obtained (fig.1). Single photon emission computed tomography scans were visually assessed.

For intraoperative detection of sentinel lymph nodes, the hand-held gamma-probe Gamma Finder II® was used, which allowed the surgeon to precisely locate gamma radiation source and obtain accurate information about the distribution of the radionuclide in tissues and organs of the patient. The intraoperative gamma probe-guidedof SLNs was performed by the surgeon after the opening of the retroperitoneal space (fig.2).The registered gamma radiation level was displayed in numerical values.



The lymph node with radioactivity of at least three times more than the background counts was defined as a sentinel lymph node. The sentinel lymph node was marked and separately sent for express cytological examination. The lymph node was sectioned transversely into 2mm slices. Depending on the size of the node, 6–10 imprints were made from each slice by gently touching the cut surface of the node onto a glass slide. Cytological specimens were stained for 15 seconds using the kit for rapid staining of blood smears (Leucodiff 200) and examined with a Zeiss Axio Scope. Patients were then underwent iliac-pelvic lymph node dissection. After lymphodissection, the removed lymph nodes were re-examined with gamma probe to detect SLNs missed during intraoperative examination(fig.3).

The true number of SLNs was calculated as the sum of SLNs identified removed lymph nodes. Statistical analysis was performed using the IBM SPSS statistics 20.0 package.

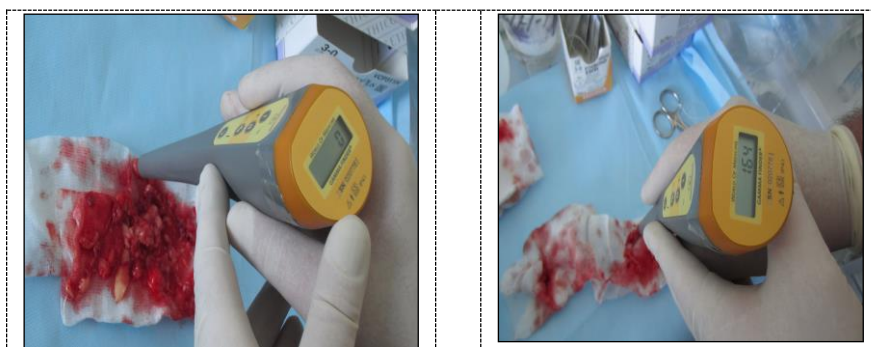

Figure 3. Direct radiometry macropreparations.

3. Results and discussion

The use of $^{99m}\text{Tc}-\text{Al}_2\text{O}_3$ enabled SLNs to be identified by SPECT and intraoperative gamma probe procedure in all 23 patients. A total of 27 SLNs were identified by means of single photon emission computed tomography (SPECT). The proportion of radiation taken up by the SLN was 7% of the total administered dose, thereby indicating high accumulation of the radiopharmaceutical in SLNs. The intraoperative SLN assessment followed by the measurement of radioactivity in surgical specimen enabled identification of 34 SLNs. The radioactive count at the tumor injection site ranged from 1500 to 2000 cps (counts per second), whereas it ranged from 80 to 200 cps in sentinel lymph nodes. The percentage of tracer uptake was 24% of the total administered dose. High radioactivity counts were registered only in SLNs, the non-SLNs had a background count (0-3cps), indicating that there was no redistribution of the radiopharmaceutical.

The most common site for SLN detection was the external iliac region (57.1%), followed by the internal iliac, obturator, presacral and retrosacral regions (they amounted to 14%, respectively), and the parametrial region (1%). The excised SLNs were evaluated by imprint cytology with subsequent routine histological examination. All lymph nodes including SLNs and non-SLNs were metastasis-negative, thereby indicating that there was no phenomenon of “jumping” nodal metastases.

The intraoperative gamma probe procedure demonstrated 100% sensitivity for SLN detection, compared to SPECT image with sensitivity of 79%.

Various techniques of SLN identification are widely discussed in the published literature. Currently, most investigators propose that the blue dye and isotope complement each other, and the detection of SLN is more successful using combined dye- isotope technique, with sensitivity and specificity approaching 100%. In our study, the use of $^{99m}\text{Tc}-\text{Al}_2\text{O}_3$, a novel molecular imaging agent has shown promising results in detecting SLNs with high sensitivity.

The frequency of lymph node metastasis in patients with stage I-II cervical cancer does not exceed 15%, which confirms the relevance of the concept of “sentinel” lymph node. The routine, widespread use of $^{99m}\text{Tc}-\text{Al}_2\text{O}_3$, specially developed for SLN identification, would greatly improve the quality of life of 80-90% of patients with early-stage cervical cancer. Sentinel lymph node biopsy may be a reasonable alternative to avoid extensive pelvic lymph nodes dissection in early stage cervical cancer patients with negative SLNs, thereby significantly reducing the length of patients’ hospital stay and speeding up their rehabilitation.

Conclusion

The novel radiopharmaceutical based on $^{99m}\text{Tc}-\text{Al}_2\text{O}_3$ has high accumulation in sentinel lymph nodes without the evidence of further redistribution along the lymphatic collector, thus significantly facilitating scintigraphic and gamma probe-guided intraoperative SLN identification.

Single photon emission computed tomography and intraoperative gamma probe-guided identification performed after paratumoral injection of $^{99m}\text{Tc}-\text{Al}_2\text{O}_3$ enable the detection of SLNs with 79 and 100% sensitivity, correspondently.

References

- [1] Edited by A.D. Caprina, V.V. Starinskaya, G.V. Petrova. 2014 *Malignancies in Russia in 2014 (morbidity and mortality)* **250s**.
- [2] VI Chernov, IG Sinilkin, ECh Choyznzonov, SY Chijevskaya, AA Titskaya, RV Zelchan, OD Bragina, AY Lyapunov, VS Skuridin. 2015 *Eur J Nucl Med Mol Imaging* **42** (Suppl 1): S 704.
- [3] I.Sinilkin, V.Chernov, R. Zelchan, A.A.Titskaya, V.Skuridin. 2014 *Eur J Nucl Med Mol Imaging* - **41** (Suppl 2) – S518
- [4] I.Sinilkin, V.Chernov, A.Chernyshova, L.Kolomiets A.Titskaya, R.Zelchan. 2015 *Advanced Materials Research Vol. 1084* pp 540-544
- [5] S.G. Afanasiev, A.V. Avgustinovich, V.I. Chernov, I.G. Sinilkin. 2009 *Siberian Journal of Oncology* №4 (34) .- S.27-32.
- [6] V.Chernov, A.Titskaya, I.Sinilkin, R.Zelchan, N.Varlamova. 2015 *Advanced Materials Research Vol. 1084* pp 443-446
- [7] V.N. Sagaidak, L.E. Komarov. 2001 *"Magazine "Practical Oncology"* - S. 45-48.
- [8] N.V. Varlamova, V.S. Skuridin, E.A. Nesterov, V.I. Chernov, A.A. Titskaya. 2015 *Experimental and Clinical Pharmacology*. T. **78**. № 6. S. 26-29.
- [9] I.Sinilkin, V.Chernov, A.Titskaya, R.Zelchan, N.Daneikina. 2015 *Advanced Materials Research Vol. 1084* pp 373-376
- [10] C. Tax, M.M. Rovers, C. de Graaf, P.L. Zusterzeel, R.L. Bekkers. 2015 *GynecolOncol*. Dec; **139** (3):559-67
- [11] R. Wuntakal, A.J.Papadopoulos, S.A.Montalto, M.Perovic, M.Coutts, O.Devaja 2015 *Int J Gynecol Cancer*. Nov;25 (9):**1663-8**.
- [12] E.A. Gould, T. Winship, P.H. Philbin, H.H. Kerr. 1960 *Cancer*; **13**: 77–78.
- [13] R.M. Cabanas. 1977 *Cancer*. **39**: 456–466.
- [14] I.G. Sinilkin, V.I. Chernov, A.L. Chernyshova, L.A. Kolomiets, A.A. Titskaya, R.V. Zelchan, O.D. Bragina, A.Y. Lyapunov, V.S. Skuridin. 2015 *Eur J Nucl Med Mol Imaging* **42** (Suppl 1): S 704